

# Strangulated Spigelian Hernia: A Diagnostic Challenge with Rare Case Report

Ajay Kumar Pal<sup>1</sup>, Mehul Saxena<sup>1</sup>, Amit Karnik<sup>1</sup>, Nasir Ansai<sup>1</sup>, Manish Kumar Agrawal<sup>1</sup>,  
Harvinder Singh Pahwa<sup>1</sup>, Awanish Kumar<sup>1</sup>, Shubhajeet Roy<sup>2</sup>

<sup>1</sup>Department of General Surgery, King George's Medical University, Lucknow, Uttar Pradesh, India.

<sup>2</sup>Gandhi Memorial and Associated Hospitals, King George's Medical University, Lucknow, Uttar Pradesh, India.

Received: 09<sup>th</sup> August, 2024; Revised: 14<sup>th</sup> August, 2024; Accepted: 08<sup>th</sup> September, 2024; Available Online: 25<sup>th</sup> September, 2024

---

## ABSTRACT

**Background:** Spigelian hernia, is a rare abdominal wall anomaly with an incidence of 0.1-2%, was initially documented by Josef Klinkosh in 1764. This hernia protrudes through the Spigelian aponeurosis, a continuation of the transversus abdominis muscle's aponeurosis situated between the rectus abdominis muscle's lateral border and the linea semilunaris. They primarily occur within the spigelian hernia belt, a region below the umbilicus delineated by the anterior superior iliac spines. These are often misdiagnosed as lateral incisional hernias (eg. port site hernia). There's no clear sex predilection, and most patients are diagnosed in the fifth or sixth decade of life.

**Methods:** A 56-year-old woman presented with acute onset and severe abdominal pain persisting for four days, accompanied by bilious vomiting. She had history of intermittent pain and swelling in left abdomen for more than 20 years and had undergone Hysterectomy with bilateral salpingo-oophorectomy 11 years earlier. Clinical examination revealed a palpable 5x5 cm lump in the left iliac fossa, with tenderness and mild erythema of overlying skin. Non-contrast abdominal CT confirmed a bowel loop protruding through an abdominal wall defect.

**Results:** Exploratory laparotomy revealed a gangrenous ileal segment of about 10 cm and segmental resection followed by anastomosis by single layer interrupted technique was done.

The patient recovered well during a 5-day hospital stay and continued follow-up without complications.

**Conclusion:** This case report emphasizes the importance of diagnosing spigelian hernia with increased risk of strangulation in patients with prior abdominal surgery. A high index of suspicion is needed for early diagnosis resulting in better outcomes.

**Keywords:** Spigelian hernia, Strangulation, Abdominal wall.

Journal of Surgery Archives (2024);

**How to cite this article:** Pal AK, Saxena M, Karnik A, Ansai N, Agrawal MK, Pahwa HS, Kumar A, Roy S. Strangulated Spigelian Hernia: A Diagnostic Challenge with Rare Case Report. Journal of Surgery Archives. 2024;2(2):38-40.

**Source of support:** Nil.

**Conflict of interest:** None

---

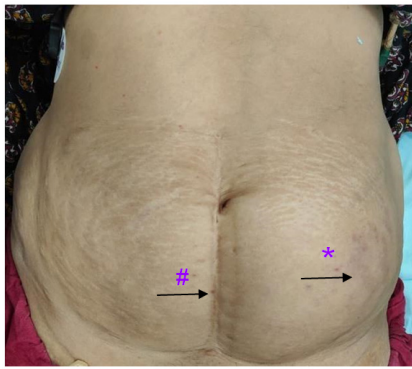
## INTRODUCTION

Spigelian hernia is a rare abdominal wall defect, first described by Josef Klinkosh in 1764, as a herniation through the Spigelian aponeurosis, an extension of the transversus abdominis muscle's aponeurosis situated between the lateral border of the rectus abdominis muscle and the linea semilunaris.<sup>1</sup> The incidence of this entity is approximated to be between 0.1 to 2% of all the abdominal hernias.<sup>2</sup> It mostly manifests within the spigelian hernia belt, which is a specific region below the umbilicus between the anterior superior iliac spines. This may be because of the parallel alignment of the internal oblique and transversus abdominis muscle fibers below the umbilicus as compared to their perpendicular arrangement above it.<sup>3</sup> They can be congenital or acquired, appear to peak around the fifth

decade, and are found to be more common in women.<sup>4</sup> We report a case of a lady aged 56 years who was diagnosed with a spigelian hernia exhibiting strangulation of the herniated bowel segment as a rare complication of a rare disease. Definitive diagnosis of a spigelian hernia is mostly made on the table, but in our case, the diagnosis of this rare complication of this rare type of hernia could be established well in advance and was managed well.

### Clinical Case

A 56 years old lady presented with complaints of pain in the left side of abdomen for the past 4 days, which was abrupt in onset, generalized in nature, and progressive in course. The patient also complained of vomiting episodes immediately



**Figure 1:** Pre-operative image showing distended and discoloured lump (\*) in the left iliac fossa along with a midline scar (#) of previous surgery.

after food or water intake. It was a projectile and consisted of food particles. There was a past history of bilateral salpingo-oophorectomy, done 11 years back for the removal of an ovarian cyst.

On examination (Figure 1), a lump of approximately 5 × 5 cm in size was palpated in the left iliac fossa along the lateral border of the rectus abdominis, approximately 16 cm below the subcostal margin, with no side-to-side mobility. The temperature was raised over the lump. Tenderness was present, and a resonant note was heard over the lump. Exaggerated bowel sounds were noted during auscultation.

Biochemical analysis revealed elevated values of serum urea (165 mg/dL), serum creatinine (4 mg/dL), serum C-reactive protein (57.5 mg/L), serum aspartate aminotransferase (136 IU/L), serum alanine aminotransferase (258.1 IU/L), prothrombin time (21.5 sec), serum troponin-T (0.08 ng/mL) and serum pro-brain natriuretic peptide (1638 pg/mL). She was found to be non-reactive for various viral markers.

The non-contrast computerized tomography (NCCT) of the abdomen (Figure 2), revealed a defect in the lateral abdominal wall consisting of a loop of bowel coming out of the defect.

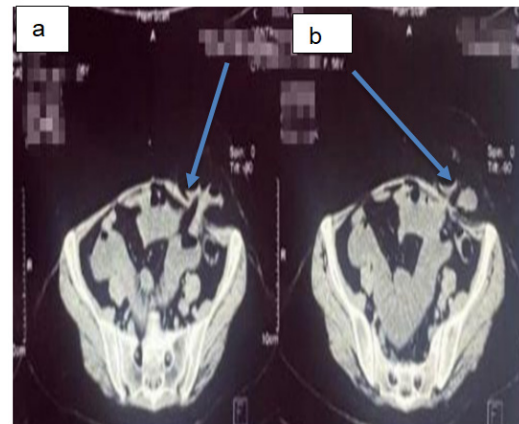
The patient was planned for exploratory laparotomy under general anesthesia. During the surgery (Figure 3), a gangrenous ileal segment was found approximately 3.5 feet distal to the duodenojejunal flexure. It was followed by ileo-ileal anastomosis.

She patient was admitted to the hospital for the next 5 days, after which she was discharged. She has been on regular follow-ups since and has shown an unremarkable recovery.

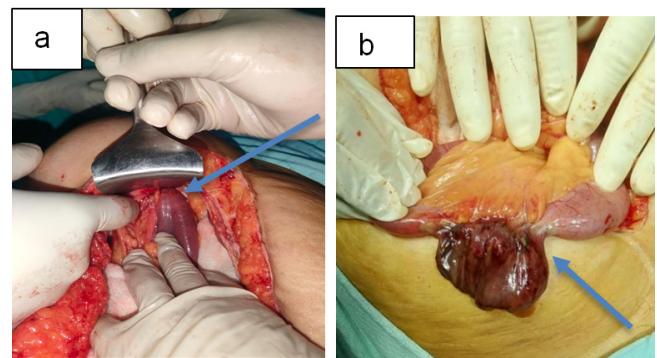
## DISCUSSION

Spigelian hernia derives its name from Adrian van der Spieghel, a 17<sup>th</sup>-century Belgian anatomist who developed the concept of the semilunar line.<sup>5</sup>

Several case series have exhibited a striking gender distribution, with 88% of patients being women, consistent with trends in other series.<sup>6</sup> It is hypothesized that multiple pregnancies and the strain associated with childbirth may contribute to the weakening of abdominal wall musculature, potentially predisposing women to spigelian hernia development.<sup>7</sup> Spigelian hernias, in most instances, arise



**Figure 2:** Pre-operative non-contrast CT image showing left abdominal wall defect (2a) containing a loop of small bowel (2b)



**Figure 3:** Intra-operative picture (a) Herniation of bowel loops inside abdominal wall (Arrow) (b). Gangrenous bowel segment (Arrow)

as acquired hernias. Predisposing factors leading to increased intraabdominal pressure and factors that attenuate the tone of oblique muscles and connective tissue integrity align with those observed in other hernia types.<sup>8</sup> In our case, a notable medical history indicated prior abdominal surgery for ovarian mass excision, potentially contributing to anterior abdominal wall muscle weakening and subsequent herniation.<sup>9</sup>

The unremarkable clinical presentation of spigelian hernia, characterized by non-specific abdominal pain and an absence of palpable mass, frequently presents as a diagnostic challenge. The diagnosis is further made challenging due to abdominal adiposity and the continuous nature of the external oblique aponeurosis.<sup>10</sup> This entity is often misdiagnosed as an inguinal hernia due to similar presentation, which explains the majority of post-laparoscopic diagnoses.<sup>11</sup> Despite this, our case was diagnosed clinically and confirmed by NCCT abdomen, which advocates for higher clinical suspicion for identifying such challenging cases, especially in patients with risk factors such as previous abdominal surgery or childbirth.

Spigelian hernia presenting with complications such as strangulation, as found in this case, is a highly rare phenomenon of an already rare disorder. Surgical intervention is indicated in such cases due to the heightened risk of strangulation (2–4%) and incarceration (24–47%), attributable to the prominent

fascial margin encompassing the defect.<sup>12-14</sup> In cases where multiple hernias are suspected, exploratory laparotomy is the preferred approach, offering a significant opportunity for simultaneous exploration and management of co-existing hernias during the procedure.<sup>15</sup> A growing proportion of cases are being addressed through laparoscopic repair leading to reduced patient morbidity and hospitalization duration.<sup>16</sup> There are three primary techniques for performing laparoscopic surgery: Total extraperitoneal (TEP), Transabdominal pre-peritoneal (TAPP), and intraperitoneal Onlay mesh (IPOM).<sup>17</sup>

## CONCLUSION

A history of previous abdominal surgery is a recognized risk factor for the subsequent development of hernias. Our case report highlights the clinical relevance of this factor and further demonstrates that herniation may not always be confined to the site of the original incision, leading to the formation of incisional hernias. Additionally, our findings indicate that rare Spigelian hernias may also occur in such cases of weakened anterior abdominal wall.

## REFERENCES

- Moreno-Egea A, Carrasco L, Girela E, Martín JG, Aguayo JL, Canteras M. Open vs laparoscopic repair of spigelian hernia: a prospective randomized trial. *Archives of surgery*. 2002 Nov 1;137(11):1266-8.
- de la Hermosa AR, Prats IA, Liendo PM, Noboa FN, Calero AM. Spigelian hernia. Personal experience and review of the literature. *Rev Esp Enferm Dig*. 2010 Oct;102(10):583-6.
- Mittal T, Kumar V, Khullar R, Sharma A, Soni V, Baijal M, Chowbey PK. Diagnosis and management of Spigelian hernia: A review of literature and our experience. *Journal of minimal access surgery*. 2008 Oct;4(4):95.
- Cinar H, Polat AK, Caglayan K, Ozbalci GS, Topgül HK, Polat C. Spigelian hernia. *Ann. Ital. Chir*. 2013;84:649-53.
- Rankin A, Kostusiak M, Sokker A. Spigelian hernia: case series and review of the literature. *Visceral medicine*. 2019 Apr 15;35(2):133-6.
- Larson DW, Farley DR. Spigelian hernias: repair and outcome for 81 patients. *World journal of surgery*. 2002 Oct;26:1277-81.
- Zalel Y, Shalev E, Romano S, Ben-Ami M, Dan U, Weiner E. Incarcerated spigelian hernia in pregnancy: an ultrasonic diagnosis. *Journal of clinical ultrasound*. 1992 Feb 1;20(2):146-8.
- White JJ. Concomitant Spigelian and inguinal hernias in a neonate. *Journal of pediatric surgery*. 2002 Apr 1;37(4):659-60.
- Morrison CP, Wemyss-Holden SA, Iswariah H, Maddern GJ. Lateral laparoscopic port sites should all be closed. *Surgical Endoscopy*. 2002 Sep 1;16(9):1364.
- Spangen L. Spigelian hernia. *World journal of surgery*. 1989 Sep;13:573-80.
- da Silva DV, Cordoval JL, Vasconcelos LH, de Menezes FM, Bastos PS, Chimeli-Ormonde L. Spigelian hernia diagnosis: Case report. *International Journal of Surgery Case Reports*. 2023 May 1;106:108165.
- Nagarsheth KH, Nickloes T, Mancini G, Solla JA: Laparoscopic repair of incidentally found Spigelian hernia. *JSLs* 2011;15:81-85.
- Moreno-Egea A, Carrasco L, Girela E, Martín JG, Aguayo JL, Canteras M. Open vs laparoscopic repair of spigelian hernia: a prospective randomized trial. *Archives of surgery*. 2002 Nov 1;137(11):1266-8.
- Leff DR, Hassell J, Sufi P, Heath D. Emergency and elective laparoscopic repair of spigelian hernias: two case reports and a review of the literature. *Surgical Laparoscopy Endoscopy & Percutaneous Techniques*. 2009 Aug 1;19(4):e152-5.
- Larson DW, Farley DR. Spigelian hernias: repair and outcome for 81 patients. *World journal of surgery*. 2002 Oct;26:1277-81.
- Moreno-Egea A, Carrasco L, Girela E, Martín JG, Aguayo JL, Canteras M: Open vs laparoscopic repair of Spigelian hernia: a prospective randomized trial. *Arch Surg* 2002;137:1266-1268.
- Malazgirt Z, Topgul K, Sokmen S, Ersin S, Turkcapar AG, Gok H, Gonullu N, Paksoy M, Ertem M. Spigelian hernias: a prospective analysis of baseline parameters and surgical outcome of 34 consecutive patients. *Hernia*. 2006 Aug;10:326-30.