

CASE REPORT

Bowel Gangrene Associated with Jejunal Diverticulosis: A Rare Case Report.

Ajay K. Pal¹, Shubhajeet Roy², Ankita Bajpai¹, Harvinder S. Pahwa¹, Awanish Kumar¹, Jaideep Soni¹

¹Department of General Surgery, King George's Medical University, Lucknow, Uttar Pradesh, India

²Faculty of Medicine, King George's Medical University, Lucknow, Uttar Pradesh, India

Received: 20th May, 2023; Accepted: 2nd June, 2023; Available Online: 25th June, 2023

ABSTRACT

A thirty-years young male presented with pain in the whole of the abdomen with intermittent vomiting and inability to pass flatus and faeces for the last four days. The patient was presented with an infrequent complication of gangrene formation in the bowel due to multiple jejunal diverticulae with acute intestinal obstruction and subsequent short bowel syndrome due to massive resection of the small bowel. The first case to be reported, to the extent of our knowledge. The management in our case involved complete resection of the gangrenous bowel, followed by the formation of jejunocolic anastomosis, which after a few days was followed by the setting up of a jejunocolic anastomosis.

Keywords: Acute intestinal obstruction, Bowel Gangrene, Jejunal Diverticulosis, Short bowel syndrome.

Journal of Surgery Archives (2023);

How to cite this article: Pal AK, Roy S, Pahwa HS, Bajpai A, Kumar A, Soni J, Bowel Gangrene Associated with Jejunal Diverticulosis: A Rare Case Report. Journal of Surgery Archives. 2023;1(1):29-30.

Source of support: Nil.

Conflict of interest: None

INTRODUCTION

Diverticulae are hollow outpouchings and are common structural abnormalities that can occur right from the esophagus to the recto-sigmoid junction. Diverticulae in the small intestine may be either congenital or acquired. Acquired diverticulae mostly develop from the jejunum, and mostly arise from the mesenteric side of the bowel due to mucosal (no muscularis layer) herniation at the point where blood vessels enter. They vary in size and are usually more than one in number.¹ We present a case of acute intestinal obstruction and short bowel syndrome due to acquired jejunal diverticulosis with a rare complication of gangrenous bowel, which was managed by exploratory laparotomy with peritoneal lavage, along with bowel resection, which was followed by setting up of a jejunocolic anastomosis twelve days later. To our knowledge, it is the first-ever case of bowel gangrene due to jejunal diverticulosis to be reported.

Case Presentation

A thirty-years young male presented with pain in the whole of the abdomen with intermittent vomiting and inability to pass flatus and faeces for the last four days. On examination, the patient had a blood pressure of 106/66 mm of Hg, pulse rate of 118/min, and respiratory rate of 20/min. The abdomen was distended with diffuse tenderness and bowel sounds were sluggish. Laboratory evaluations showed Leucocytosis with TLC of 18,000/mm³. His liver function test showed his slightly

raised ALT levels of 60IU/L with rest being normal. Kidney Function tests were in the normal range. He had raised serum amylase, CRP levels (240 mg/dL), and Lactate levels of 5 mg/dL; Prothrombin time of 20.2 seconds, and INR was 1.59. He was planned for surgery based on clinico-radiological suspicion of Acute Abdomen with generalized Peritonitis. Therefore he was finally diagnosed as a case of acute intestinal obstruction with small bowel gangrene with multiple jejunal diverticulosis on the mesenteric side (starting from 1 foot distal to DJ flexure) as he underwent exploratory laparotomy with peritoneal lavage and the gangrenous diseased bowel was resected (Figure 1), under general anesthesia. The jejunocolic anastomosis was made three feet distal to duodeno-jejunal flexure, and the patient was put on a single pelvic drain. Postoperatively, patient stoma output monitoring was done and the patient was nutritionally built up with enteral and parenteral nutrition for early restoration of bowel continuity. The drain was removed on the fourth postoperative day. After 28 days, the patient then underwent a restoration of bowel continuity by means of a jejunocolic anastomosis, under general anesthesia. The patient was then discharged with general fair conditions and stable vitals and was allowed a full oral diet.

DISCUSSION

Jejunal diverticulae are a rare finding, with 0.0006–1.4% reporting in all small bowel contrast studies, 0.3–4.6% autopsies, and 2.3% enteroclysis.² These are pulsion

*Author for Correspondence: akpal.jnmc@yahoo.com.

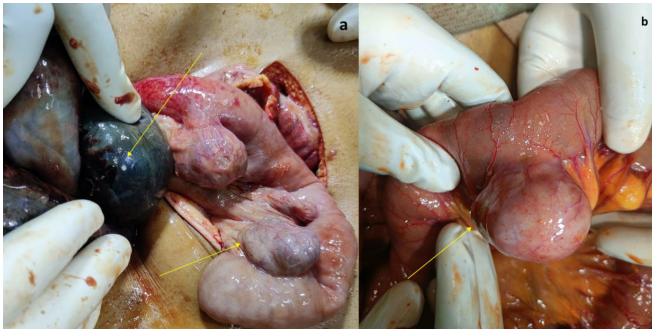


Figure 1: a. Intraoperative view of the gangrenous bowel loops along with the jejunal diverticulae (arrows). b. Arrow showing well-defined diverticula located on mesenteric border of jejunum.

diverticulae due to intestinal dyskinesia. Patients present with complaints of chronic abdominal pain, malabsorption, anemia, gastrointestinal bleeding, intestinal obstruction, bacterial stasis, and distension.³ Common complications include obstruction, perforation, inflammation, hemorrhage, and malignancy.⁴

In our case, the patient presented with an infrequent complication of gangrene formation in the bowel due to multiple jejunal diverticulae with acute intestinal obstruction and subsequent short bowel syndrome due to massive resection of the small bowel. The extent of the gangrenous portion of the bowel was from one foot distal to the duodeno-jejunal flexure till the ileo-cecal junction.

In a case reported by Falidas E *et al.* in 2011, a 55-years-old man presented with acute abdominal pain, vomiting, and fever. Preoperative imaging and laparotomy revealed intestinal obstruction caused by multiple giant jejunal diverticulae.⁵ In another case by Ghrissi R *et al.*, a 72-years-old patient had several episodes of vomiting and abdominal distension but no fever or peritonitis. On exploratory laparotomy, jejunal, colonic, and bladder diverticulae were found, from which adhesion bands were formed to the abdominal wall and the small intestine, which led to intestinal obstruction.⁶ In yet another case by Lin CH *et al.*, a 70-years-old man had suffered three episodes of intestinal obstruction in a year and experienced dull pain and fullness over the whole abdomen, which couldn't be relieved by medications and exploratory laparotomy revealed diverticulosis of the proximal jejunum with adhesion bands formed from the base of one of the diverticulae.⁷ Bassem NA *et al.* reported intestinal obstruction for three days in a 47-years-old woman after exploratory laparotomy proximal jejunal diverticulae with adhesion epiploic band and strangulation of jejunum were found.⁸

In most cases mentioned above, the jejunal diverticulae-led intestinal obstruction occurred due to band formation. We couldn't find a single reported case report in the literature pertaining to bowel gangrene formation due to jejunal diverticulosis, after our search in PubMed and Google Scholar using the keywords "gangrenous jejunal diverticulosis", "jejunal diverticula", "gangrene", "gangrenous bowel", thus making ours the first case to be reported, to the extent of our knowledge.

The management in our case involved complete resection of the gangrenous bowel, followed by the formation of jejuno-ascending stoma, which after a few days was followed by the setting up of a jejuno-colic anastomosis.

CONCLUSION

Jejunal diverticulosis, although a rare cause of acute or chronic abdominal pain symptoms, may lead to obstruction, perforation, inflammation, and hemorrhage complications. Obstruction leading to bowel gangrene is even rarer in the cases encountered until jejunal diverticulosis.

REFERENCES

1. Williams NS, O'Connell PR, McCaskie AW. Bailey & Love's Short Practice of Surgery. 27th ed. Boca Raton (FL): CRC Press; 2018. p.1632. <https://doi.org/10.1201/9781315111087>.
2. Cooke WT, Cox EV, Fone DJ, Meynell MJ, Gaddie R. The clinical and metabolic significance of jejunal diverticula. *Gut*. 1963;4(2):115–131. <https://doi.org/10.1136/gut.4.2.115>.
3. Palder SB, Frey CB. Jejunal diverticulosis. *Arch Surg*. 1988;123(7):889–894.
4. Lee RE, Finby N. Jejunal and ileal diverticulosis. *AMA Arch Intern Med*. 1958;102(1):97–102.
5. Falidas E, Vlachos K, Mathioulakis S, Archontovasilis F, Villias C. Multiple giant diverticula of the jejunum causing intestinal obstruction: report of a case and review of the literature. *World Journal of Emergency Surgery*. 2011 Dec;6(1):1-9.
6. Ghrissi R, Harbi H, Elghali MA, Belhajkhelifa MH, Letaief MR. Jejunal diverticulosis: a rare case of intestinal obstruction. *Journal of Surgical Case Reports* 2016:1–3. doi: 10.1093/jscr/rjv176
7. Lin CH, Hsieh HF, Yu CY, Yu JC, Chan DC, Chen TW, *et al.* . diverticulosis of the jejunum with intestinal obstruction: A case report. *World J Gastroenterol* 2005;11(34): 5416-5417. <http://www.wjgnet.com/1007-9327/11/5416.asp>
8. Nejmeddine A, Bassem A, Mohamed H, Hazem BA, Ramez B, Issam BM. Complicated jejunal diverticulosis: a case report with literature review. *North Am J Med Sci* 2009; 1: 196-199.